

## **Vaginal Calculi in a Juvenile Harbor Porpoise (*Phocoena phocoena*)**

Author(s): Stephanie A. Norman, D.V.M., M.S., Michael M. Garner, D.V.M., Dipl. A.C.V.P., Susan Berta, B.A., Sandra Dubpernell, B.A., M.S., and Matthew Klope, B.S.

Source: Journal of Zoo and Wildlife Medicine, 42(2):335-337. 2011.

Published By: American Association of Zoo Veterinarians

DOI: <http://dx.doi.org/10.1638/2010-0168.1>

URL: <http://www.bioone.org/doi/full/10.1638/2010-0168.1>

---

BioOne ([www.bioone.org](http://www.bioone.org)) is a nonprofit, online aggregation of core research in the biological, ecological, and environmental sciences. BioOne provides a sustainable online platform for over 170 journals and books published by nonprofit societies, associations, museums, institutions, and presses.

Your use of this PDF, the BioOne Web site, and all posted and associated content indicates your acceptance of BioOne's Terms of Use, available at [www.bioone.org/page/terms\\_of\\_use](http://www.bioone.org/page/terms_of_use).

Usage of BioOne content is strictly limited to personal, educational, and non-commercial use. Commercial inquiries or rights and permissions requests should be directed to the individual publisher as copyright holder.

## VAGINAL CALCULI IN A JUVENILE HARBOR PORPOISE (*PHOCOENA PHOCOENA*)

Stephanie A. Norman, D.V.M., M.S., Michael M. Garner, D.V.M., Dipl. A.C.V.P., Susan Berta, B.A., Sandra Dubpernell, B.A., M.S., and Matthew Klope, B.S.

**Abstract:** A large number of vaginal calculi were observed in a juvenile harbor porpoise (*Phocoena phocoena*) stranded on Whidbey Island, Washington. Vaginal calculi have been reported in other species, but not in harbor porpoises. Histologic examination of the urinary tract revealed mucosal hyperplasia most likely attributable to the calculi. The calculi were numerous (>30), composed completely of struvite (magnesium ammonium phosphate), and on culture yielded *Enterococcus* spp., a bacterium not usually associated with struvite urolith formation in domestic animals. The only other lesion of note was severe hepatic lipidosis, and its relationship to the development of the vaginal calculi is unknown.

**Key words:** Harbor porpoise, hepatic lipidosis, *Phocoena phocoena*, struvite, vaginal calculi.

### BRIEF COMMUNICATION

Vaginal calculi have not been previously reported in harbor porpoises (*Phocoena phocoena*) but have been observed in bottlenose dolphins (*Tursiops truncatus*), common dolphins (*Delphinus delphis*), Pacific white-sided dolphins (*Lagenorhynchus obliquidens*), Peruvian dusky dolphins (*Lagenorhynchus obscurus*), and spotted dolphins (*Stenella attenuata*).<sup>7,12,15,17</sup> However, struvite (magnesium ammonium phosphate hexahydrate) calculi have only been documented in the bottlenose dolphin and pygmy sperm whale (*Kogia breviceps*).<sup>4,7</sup> In this report, struvite calculi in the vaginal tract of a stranded harbor porpoise, as the primary debilitating feature discovered during necropsy, is described.

A 96.3-cm female harbor porpoise (*Phocoena phocoena*) was found dead on 17 January 2010 on Whidbey Island, Washington (48°43'N, 122°6'W), and immediately transported to a Central Puget Sound Marine Mammal Stranding Network necropsy facility on Whidbey Island (Field No. 10Pp17JanWI-01). Age was estimated to be 1 yr, based on the animal's length (teeth were not aged).<sup>14</sup> The carcass was fresh, with minimal scavenging, and in good nutritional status. Blubber thickness was measured halfway between the insertions of the dorsal and pectoral fins dorsally (2.0 cm), laterally (2.3 cm), and ventrally (2.3 cm).

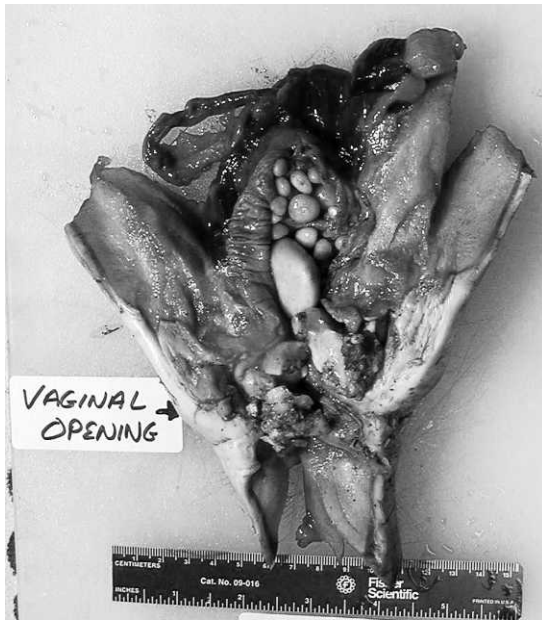
Primary gross lesions were confined to the hepatic and urogenital systems. Necropsy revealed large numbers of variably sized, tan/yellow to light yellowish green, smooth calculi in the urogenital slit, vagina, and cervix (Fig. 1); an enlarged, firm, pale-yellow to tan liver (Fig. 2); pale kidneys and an empty urinary bladder. Calculi ranged in size from 2 mm to 3 cm, and the largest weighed 10 g.

Formalin-fixed tissues (Accession No. G10-0682) were processed routinely and examined histologically. Mucosa from the distal urogenital tract had moderate hyperplasia and orderly maturation with no dysplasia or inclusions. The liver had diffuse, severe hepatocellular lipidosis with moderate intracellular yellow granular material interpreted as bile (cholestasis). Other histologic findings included diffuse, markedly congested and edematous pulmonary parenchyma, and moderate to marked congestion of the blood vessels of all the lymph nodes, kidneys, eyes, brain, meninges, and adrenal glands, consistent with acute shock. Lymphoid cellularity was moderately depleted in the lymph nodes and thymus, and a few nodes had mild hemosiderosis in the medullary sinuses. Low numbers of scattered necrotic myofibers were noted in the ventricles of the heart. No histologic lesions were noted in any other organs.

Calculi (Accession No. 586942-A, 9603.S) submitted to the Minnesota Urolith Center, University of Minnesota, College of Veterinary Medicine (St. Paul, Minnesota, USA) for qualitative analysis of mineral composition by polarizing light microscopy were 100% struvite.<sup>6</sup> Stone culture was performed at Phoenix Central Laboratory (PCL) (Everett, Washington, USA) and revealed pure culture of *Enterococcus* spp. Vitreous humor was collected from the left eye and submitted to PCL for a chemistry screen. The most notable

---

From Marine-Med: Marine Research, Epidemiology, and Veterinary Medicine, 24225 15th Place Southeast, Bothell, Washington 98201, USA (Norman); Northwest ZooPath, 654 West Main Street, Monroe, Washington 98272, USA (Garner); and Central Puget Sound Marine Mammal Stranding Network, 2403 North Bluff Road, Greenbank, Washington 98253, USA (Norman, Berta, Dubpernell, Klope). Correspondence should be directed to Dr. Norman (whaledoctor@gmail.com).



**Figure 1.** Multiple calculi in the urogenital slit and vagina of a harbor porpoise (*Phocoena phocoena*).

abnormality was an elevated aspartate aminotransferase (AST = 2,289 U/L).

Although most vaginal calculi in cetaceans are of unknown origin, it has been suggested that they represent concretions of seminal fluid, vaginal mucus, or crystallized fetal remnants.<sup>12,17</sup> However, given the present animal's reproductive immaturity and accompanying hepatic lipidosis, a more plausible explanation for the calculi is that they originated subsequent to an infection of the urinary tract or other organ system, as described in previous studies.<sup>7,15</sup> A heavy burden of the cestode *Monorygma* spp. has been associated with vaginal calculi in the reproductive tract of a common dolphin.<sup>17</sup> In the common dolphin, it was hypothesized that the parasitic infection may have served as a nidus for the formation of the vaginal calculi. The harbor porpoise in this report did not show any overt signs suggestive of parasitism, particularly within the urogenital tract. In domestic dogs, struvite uroliths tend to occur more commonly in females due to the prevalence of urinary tract infections, whereas the reverse is true in cats.<sup>11</sup> To date, struvite calculi have been observed more frequently than other types of calculi in cetaceans, which may reflect a higher prevalence of urinary tract infections rather than other causes of uroliths.

*Enterococcus* spp. are Gram-positive, facultatively anaerobic organisms that are found in the intestinal tract of most mammals, including harbor



**Figure 2.** Cross-section of the liver in a juvenile harbor porpoise (*Phocoena phocoena*) with severe hepatic lipidosis.

porpoises, but may reside in other sites such as the vagina and oral cavity.<sup>10</sup> They may be associated with endocarditis, bacteremia, and urinary tract infections and are one of the most commonly isolated pathogens from urinary tract infections in domestic dogs.<sup>1,10</sup> Struvite stones are almost always the result of long-standing urinary tract infection with urease-producing bacteria, which include *Proteus* spp. (most common), *Ureaplasma* spp., *Klebsiella* spp., *Staphylococcus* spp., and *Pseudomonas* spp.; however, *Enterococcus* spp. are not usually associated with struvite stone formation.<sup>2</sup> The calculi observed in this porpoise may have resulted from either preexisting colonization of the reproductive or urinary tract by *Enterococcus* (serving as a nidus for stone formation) or an underlying metabolic condition, as is frequently observed in human children.<sup>9</sup> In this harbor porpoise, obvious inflammation of the urinary tract was not evident on histologic examination of urinary tract sections. It is possible that sufficient time had elapsed following voiding of the calculi through the urethra for a urinary tract infection to resolve.

Hepatic lipidosis has been described in several cetacean species, including harbor porpoises, pilot whales (*Globicephala macrorhynchus*), pygmy sperm whales, a sperm whale (*Physeter macrocephalus*), and a Gervais' beaked whale (*Mesoplodon europaeus*).<sup>13</sup> It is considered a relatively common finding in stranded cetaceans that present with metabolic disorders produced by toxic injuries or nutritional deficiencies and was noted in 27–50% of harbor porpoises examined in several populations.<sup>3,13</sup> It may also be associated with environmental toxins and biologic agents such as viruses, bacteria, fungi, and parasites. Hepatic lipidosis often presents in

stranded animals that are severely starved, or in nursing animals that are ingesting a high dietary intake of carbohydrates, where excessive triglycerides may accumulate within hepatocytes.<sup>5</sup> This animal was in good nutritional status, was not obese, and was considered too old to be consuming high quantities of carbohydrates such as milk.

Because of the absence of urine in the urinary bladder, and suitable postmortem blood for analysis, confirmation of abnormal hepatic function and other metabolic processes was only possible through analysis of vitreous humor. Biochemical analytes of vitreous humor have been evaluated in West Indian manatees (*Trichechus manatus latirostris*) and horses and have been found to have potential for assisting in the postmortem diagnosis of certain renal, nutritional, and metabolic diseases.<sup>8,16</sup> These analytes may provide a useful and accurate estimation of antemortem concentrations and may allow extrapolation to corresponding serum values. However, caution should be used, as eye-fluid analytes have not been validated in any animal species and may be affected by postmortem time and temperature. In this porpoise, the extremely high AST noted may correlate with the observed severe hepatic lipidosis but may also be associated with the enzyme's release into the ocular fluid from the cytoplasm of autolytic or traumatized ocular cells during fluid collection.<sup>3</sup>

Severe vaginal calculi in a juvenile harbor porpoise is reported in the present case. The hepatic lipidosis may have been a consequence to an infection that precipitated the urolith formation or, based on the clinical and histological findings in conjunction with the animal's age, this porpoise may have had some form of congenital metabolic derangement. However, debility from potential metabolic disturbances may have also compounded other adverse conditions not detected in the examinations. If additional porpoises with similar lesions are found in the region, an environmental influence should also be considered possible.

*Acknowledgments:* Mary Jo Adams and Mahmoud M. Abdel-Monem assisted with the necropsy and sample collection, and Leroy Brown of Histologic Consulting Service consulted on the histotechnology and slide preparation. This work was funded by the John H. Prescott Marine Mammal Rescue Assistance Grant Program (FNA08NMF4390558).

#### LITERATURE CITED

1. Ball, K. R., J. E. Rubin, M. Chirino-Trejo, and P. M. Dowling. 2008. Antimicrobial resistance and prevalence of canine uropathogens at the Western College

of Veterinary Medicine Veterinary Teaching Hospital, 2002–2007. *Can. Vet. J.* 49: 985–990.

2. Griffith, D. P., and C. A. Osborne. 1987. Infection (urease) stones. *Miner. Electrolyte Metab.* 13: 278–285.

3. Hanna, P. E., J. E. C. Bellamy, and A. Donald. 1990. Postmortem eye fluid analysis in dogs, cats and cattle as an estimate of antemortem serum chemistry profiles. *Can. J. Vet. Res.* 54: 487–494.

4. Harms, C. A., R. L. Piccolo, D. S. Rotstein, and A. A. Hohn. 2004. Struvite penile urethrolithiasis in a pygmy sperm whale (*Kogia breviceps*). *J. Wildl. Dis.* 40: 588–593.

5. Howard, E. B. 1983. Miscellaneous diseases. *In:* Howard, E. B. (ed.). *Pathology of Marine Mammals Disease*, vol. 2. CRC Press, Boca Raton, Florida. Pp. 163–171.

6. Lulich, J. P., and C. A. Osborne. 2009. Changing paradigms in the diagnosis of urolithiasis. *Vet. Clin. North Am. Small Anim. Pract.* 39: 79–91.

7. McFee, W. E., and C. A. Osborne. 2004. Struvite calculus in the vagina of a bottlenose dolphin (*Tursiops truncatus*). *J. Wildl. Dis.* 40: 125–128.

8. McLaughlin, B. G., and P. S. McLaughlin. 1988. Equine vitreous humor chemical concentrations: correlation with serum concentrations, and postmortem changes with time and temperature. *Can. J. Vet. Res.* 52: 476–480.

9. Milliner, D. S., and M. E. Murphy. 1993. Urolithiasis in pediatric patients. *Mayo Clin. Proc.* 68: 241–248.

10. Murray, B. E. 1990. The life and times of the *Enterococcus*. *Clin. Microbiol. Rev.* 3: 46–65.

11. Osborne, C.A., J. P. Lulich, J. M. Kruger, L. K. Ulrich, and L. A. Koehler. 2009. Analysis of 451,891 canine uroliths, feline uroliths, and feline urethral plugs from 1981 to 2007: perspectives from the Minnesota Urolith Center. *Vet. Clin. North Am. Small Anim. Pract.* 39: 183–197.

12. Sawyer, J. E., and W. A. Walker. 1977. Vaginal calculi in the dolphin. *J. Wildl. Dis.* 13: 346–348.

13. Siebert, U., A. Wünschmann, R. Weiss, H. Frank, H. Benke, and K. Frese. 2001. Post-mortem findings in harbor porpoises (*Phocoena phocoena*) from the German and North Baltic Seas. *J. Comp. Pathol.* 124: 102–114.

14. Simons, L. S. 1984. Seasonality of reproduction and dental structures in the harbor porpoise (*Phocoena phocoena*) of the North Pacific. *J. Mammal.* 65: 491–495.

15. Van Bresseem, M. F., K. Van Waerebeek, U. Siebert, A. Wünschmann, L. Chavez-Lisambart, and J. C. Reyes. 2000. Genital diseases in the Peruvian dusky dolphin (*Lagenorhynchus obscurus*). *J. Comp. Pathol.* 122: 266–277.

16. Varela, R. A., and G. D. Bossart. 2005. Evaluation of biochemical analytes in vitreous humor collected after death in West Indian manatees. *J. Am. Vet. Med. Assoc.* 226: 88–92.

17. Woodhouse, C. D., and C. J. Rennie, 3rd. 1991. Observations of vaginal calculi in dolphins. *J. Wildl. Dis.* 27: 421–427.

*Received for publication 17 November 2010*